

Intracystic papillary carcinoma (IPC) is one of the rare malignant tumours of the breast. It occurs communally in postmenopausal women with average age between 55 and 67 years old. It can be clinically asymptomatic, or it presents with a breast mass or areolar changes. Using imaging techniques, IPC is usually characterised by benign features. IPC should be considered in the evaluation and differential diagnosis of cystic lesions observed in postmenopausal women, and it has a more positive prognosis than that of ductal carcinoma in situ (DCIS). Although segmental mastectomy is recommended for the treatment of such lesions, no universal consensus exists on adjuvant therapies. In this case study, the authors present two female patients, aged 68 and 43 years, diagnosed with IPC, with reference to the literature.

Key words: intracystic papillary carcinoma, breast cancer, radiotherapy.

Contemp Oncol (Pozn) 2014; 18
special issue
DOI: 10.5114/wo.2014.40592

Intracystic papillary carcinoma of the breast in females: two case reports

Emine Canyilmaz¹, Gonca Hanedan Uslu¹, Sevdegül Mungan², Lasif Serdar¹, Zümrüt Bahat², Feyyaz Özdemir³, Ahmet Sari¹

¹Department of Radiation Oncology, Faculty of Medicine, Karadeniz Technical University, Trabzon, Turkey

²Department of Pathology, Faculty of Medicine, Karadeniz Technical University, Trabzon, Turkey

³Department of Medical Oncology, School of Medicine, Karadeniz Technical University, Trabzon, Turkey

Introduction

Intracystic papillary carcinoma (IPC) is one of the rare malignant tumours of the breast, accounting for 0.5–1% of all patients diagnosed with carcinoma of the breast. IPC cases are associated with a good prognosis, and are typically observed in postmenopausal women [1, 2]. In the literature, only a few cases have reported the occurrence of IPC in women under 40 years old [3]. It is difficult to diagnose IPC as there is no standard defined criterion for its diagnosis, treatment or clinicopathological characteristics. Typically, the tumour is asymptomatic; however, it can manifest as a breast mass or a nipple discharge. On ultrasonography, IPC can be a pure cyst, a solid mass or a mixed image. On mammography, it appears as a round, oval or lobulated opacity. The mass margins are usually well-circumscribed. Magnetic resonance imaging of the breast with contrast may show marked enhancement of cyst walls, septations and mural nodules [4]. Core needle biopsy or Tru-cut biopsy have been used by many authors in order to distinguish benign from malignant papillary lesions. However, excisional biopsy is often needed for diagnostic purposes [3].

The IPC tumours are not invasive in nature. Intracystic papillary carcinoma can be present in a pure form, or can be associated with DCIS or invasive carcinoma [1, 2]. Papillomas are typically found in a capsule-like structure in the ducts. Additionally, a cyst containing a blood clot and an intracystic neoplasm should be included in the differential diagnosis [5].

Treatment of IPC is also still controversial. Intracystic papillary carcinoma may be managed by mastectomy or segmental resection. There has been no randomised controlled trial comparing breast conserving surgery to mastectomy [6]. Radiation therapy and endocrine therapy are used by many centres, but evidence of their role in prognosis improvement is still lacking [7].

In the past, no clear distinctions were made between these types of cancer, which led to the consideration that IPC has a poor prognosis. However, today it is common knowledge that patients with IPC have better prognoses than those with ductal carcinomas [1, 8]. Solaranzo *et al.* reported the 10-year general survival rate to be 100% and the disease-free survival rate to be 91%, in their series of IPC. A study by Grabowski *et al.*, evaluating the 10-year results of cases with IPC with and without invasions, reported that the presence of an invasion had no statistically significant effects on prognosis, and that the long-term survival was very good [9, 10]. No disease-caused mortalities have been reported, and recurrence is rare in pure intracystic papillary carcinomas.

The present paper discusses this rare tumour of the breast in two patients with IPC, with reference to the literature.

Case 1

A sixty-eight-year-old postmenopausal patient was admitted to the hospital after noticing a palpable mass in the right breast. Aside from having five children, the patient had nothing particularly noteworthy in her family history.

Physical examination revealed a 2 cm mass, non-well defined, fixed and firm, non-painful and without skin changes. There were no axillary nodes. Her breast mammographic studies showed an irregular cystic mass, 18 mm × 22 mm, showing micro-calcification in the upper inner quadrant of the right breast (Fig. 1.). Her preoperative abdominal and thoracic tomography showed no distant metastasis. The patient was treated with lumpectomy to remove the cystic lesion. Sentinel lymph node biopsy

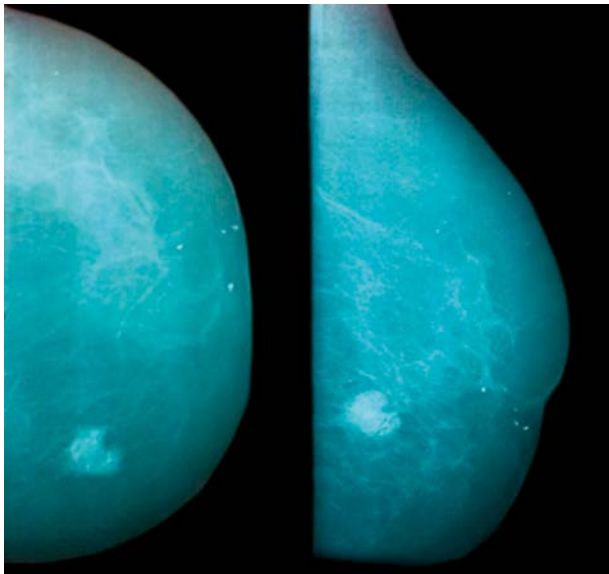


Fig. 1. Irregular cystic mass showing micro-calcification, 18 mm × 22 mm, (case 1)

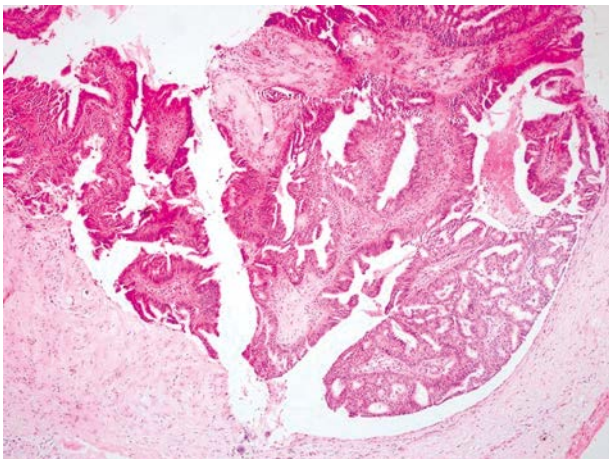


Fig. 2. Microscopy shows the neoplastic development forming papillary structures in the cystic cavity (HE, 40×) (case 1)

(SLNB) was performed on the patient using 1% isosulfan blue injection for the evaluation of the axillary. The patient was discharged without postoperative complications. The macroscopic examination showed a 1.5 cm solid lesion, and closest surgical margin was 1 cm. Microscopy showed papillary structures with low grade atypical cells laid on a fibrovascular stroma. Thin layers of cubic epithelium were observed on the cyst wall. There was no staining on the myoepithelial layer upon immunohistochemical examination. In addition, no invasion was detected on serial sections, and intracystic papillary carcinoma was diagnosed. Microscopic examination showed an intracystic papillary carcinoma with strongly positive oestrogen and progesterone receptors. Cerb-B2 was found to be negative, and no metastasis was found in the 3 removed sentinel lymph nodes (Figs. 2, 3). Low-degree ductal carcinoma foci were observed sporadically in the surrounding breast tissues. The patient was treated with four courses of epirubicine and cisplatin, postoperatively, and 50-Gy radiotherapy was applied to the entire breast from the internal-external tangential field at our clinic with a 6 MV linear accelerator (Varian-Clinac) at 200 cGy/fx. The patient received Tamoxifen (40 mg) treatment post-radiotherapy and is now at month 18 of her follow-up; her physiological and radiological examinations so far have shown no local or systemic recurrences.

Case 2

A forty-three-year-old premenopausal patient was admitted to the hospital after noticing a mass in the right breast. A side from having three children, the patient had nothing particularly noteworthy in her personal medical history and family history.

Her physical examination showed a moderately hard mass, about 2 cm in diameter, localised on the right nipple. There were no palpable lymph nodes in the armpits. Her breast ultrasound showed a 19 mm × 10 mm high-concentration ductal ectasia neighbouring the right breast areola (Fig. 4). The mass at 7 o'clock on the right breast was excised. Macroscopic examination of the specimen showed a hemorrhagic cystic component in

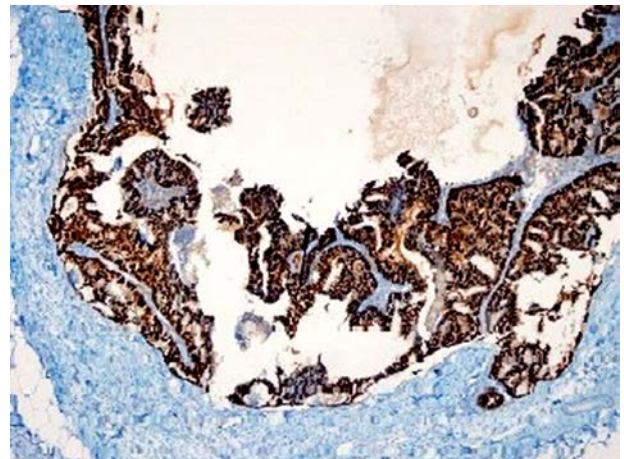


Fig. 3. Neoplastic development reveals a diffuse positive oestrogen receptor (IHK, 100×) (case 1)

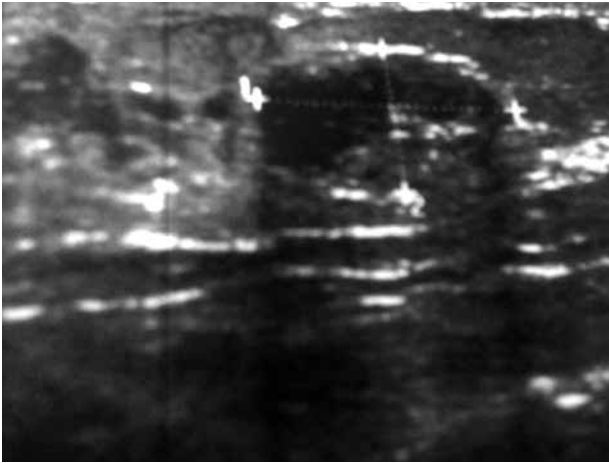


Fig. 4. Areola of the right breast ductal ectasia adjacent to the dense content (case 2)

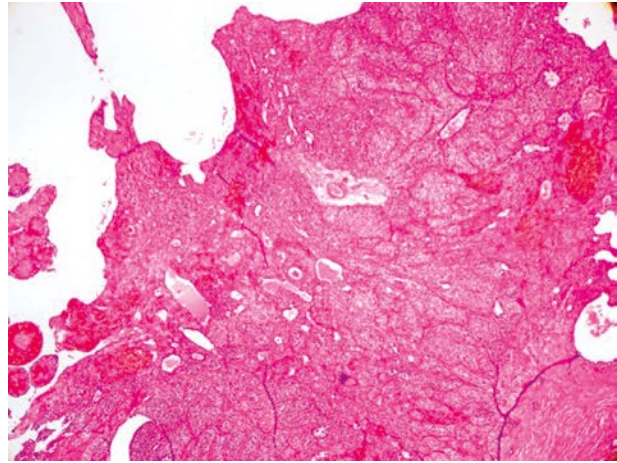


Fig. 5. Microscopy shows the neoplastic development forming papillary structures in the cystic cavity (HE, 40×) (case 2)

the cross-sectional surface. Macroscopic examination showed a cystic-solid papillary neoplasm protruding into the peripheral major cystic ducts and surrounding the intraductal carcinoma areas with comedo necrosis in the cross sections. The papillary neoplasm consisted of atypical epithelial cells showing a solid development pattern and high mitosis activity, with thin fibrovascular cores in the cyst. The lesion was limited, with no stromal invasion observed peripherally. On one edge of the excision border, there was an intraductal carcinoma focus terminating at the excision site. Immunohistochemical examination showed no myoepithelial layer staining (Fig. 5). The diameter of the tumour was 1.2 cm, with strongly positive oestrogen and progesterone receptors. *Cerb-B2* was found to be negative. Ten days later, a sentinel lymph node biopsy (SLNB) was performed on the patient using 1% isosulfan blue injection to evaluate the re-excision of the initial excision site and the axillary. With no postoperative complications, the patient was discharged the following day. Her pathology was reported as ductal carcinoma in situ, 2.5 cm × 3 cm, around the initial excision site, nuclear grade 3, with no detection of necrosis and calcification and with the nearest surgical margin being 1 cm. There was no metastasis in the two removed sentinel lymph nodes. The patient received 50-Gy radiotherapy postoperatively to the entire breast from the internal-external tangential field at our clinic with a 6 MV linear accelerator (Varian-Clinac) at 200 cGy/fx and was treated with tamoxifen due to a positive hormone receptor. The patient is now at month 25 of her follow-up, and her physiological and radiological examinations have shown no local and systemic recurrences so far.

Discussion

Although breast cysts are very common lesions, cystic carcinomas of the breast are rare. The most common cystic carcinomas are intracystic papillary adenocarcinoma, invasive ductal adenocarcinoma with cystic degeneration, medullary carcinoma, mucinous carcinoma, adenoid cystic carcinoma and squamous carcinoma [11]. The prevalence of IPCs should be considered when a cystic breast mass

is detected in postmenopausal women. Of the two cases we have presented, one was premenopausal and the other one was diagnosed during the postmenopausal period. IPC cases during the premenopausal period were rarely reported in the literature [3].

Intracystic papillary carcinoma is an uncommon breast disease, constituting 0.5% to 1% of all breast cancers [1]. Intracystic papillary carcinoma, which may be unifocal or multifocal, has a propensity to occur in postmenopausal women. Most women with intracystic papillary carcinoma have no symptoms. In some cases, they may present with a palpable mass or nipple discharge as the initial finding. They are usually localised under the right areola in large masses [4]. Both cases we have presented had a mass on the right breast, in agreement with the literature. Ultrasonography typically shows a hypoechoic area (the cyst) with soft tissue echoes projecting from the wall of the cyst (intracystic tumour). Generally, the mammographic pattern of an intracystic papillary carcinoma is a round, oval or lobulated mass. The mass margins are usually circumscribed, but may be obscured or unclear [12]. Magnetic resonance imaging (MRI) is sensitive but not specific in detecting papillary tumours. Both of the cases we have presented had ultrasonography and mammography findings in agreement with the literature. Papillary neoplasms can be diagnosed by fine-needle aspiration and core needle biopsy. False negative results with cytology are relatively frequent since fine-needle aspiration and core needle biopsy often target the centre of the lesion. Invasion in IPC is usually found at the periphery of the tumour. Therefore, excisional biopsy is suggested for diagnosis [13]. Neither of the two cases presented had fine needle aspiration biopsy.

Intracystic papillary carcinoma can be present in a pure form or can be associated with invasive ductal carcinoma. Lefkowitz *et al.* [9] reported in their 77-case IPC series that these tumours present with DCIS at a rate of 36%, and invasive carcinoma at a rate of 12%. Carter *et al.*'s [14] 41-case series found the rate of DCIS associated with IPC to be 46%, and Leal *et al.*'s [15] 29-case series found the invasion rate to be 38%. If IPC coexists with another type of

Table 1. Algorithm for the treatment of papillomas

Discharge: physical examination, mammography, and/or ultrasound <i>No significant abnormality, benign: MD + ductal lavage +/- biopsy</i>
Evidence of malignancy MD-guided BCS, mastectomy
No evidence of malignancy Symptomatic: MD-guided microdochectomy Not symptomatic: reassure, conservative treatment
Significant abnormality: imaging-guided core biopsy/ mammotome –
MRI-MD and ductal lavage biopsy
Evidence of malignancy MD-guided BCS, mastectomy
No evidence of malignancy Symptomatic: MD-guided microdochectomy Not symptomatic: reassure, conservative treatment
Microcalcifications/indeterminate mass/malignant cytology

MD – mammary ductoscopy; BCS – breast-conserving surgery; MRI – magnetic resonance imaging

carcinoma, then treatment and prognosis are determined on the basis of the associated pathology.

The treatment of IPC is still controversial, and the mainstays of treatment are conservative surgery or mastectomy in the light of the series of cases under review. However, mastectomy is not the preferred treatment modality due to its low local recurrence and low distant metastasis rate. Since axillary lymph node metastasis is observed at a rate of 14%, some researchers recommend axillary lymph node dissection. However, other researchers argue that IPCs are typically in situ diseases, and therefore they do not recommend axillary dissection [16, 17].

Fayanju *et al.* recently reviewed the adjuvant treatment usually applied in cases of IPC and found that patients with DCIS or microinvasive diseases in association with IPC were more likely to receive radiotherapy and tamoxifen. A new proposed algorithm for the treatment of papillomas is shown in Table 1 [16–18].

Today, the effectiveness of radiotherapy and endocrine therapy is not clear in these types of carcinomas. A study by Solorzano *et al.* [1] applied radiotherapy to 30% of the cases with intracystic papillary carcinoma. The group emphasised that whether or not radiotherapy was applied had no effect on recurrence and survival. Another study reported that radiotherapy and hormone therapy could be given, particularly in high nuclear grade intracystic papillary carcinoma cases younger than 50 years old, and that the decision should be made on a case-by-case basis [19, 20].

Conservative surgery was performed in both of these cases; the first case received chemotherapy and radiotherapy, whereas the second case received only radiotherapy post-surgically. Both cases were administered tamoxifen because of oestrogen receptor positivity. Conservative surgery was performed in both cases and the axilla was

evaluated by SLND. Because no metastasis was found in the sentinel lymph node, axillary dissection was not performed.

We conclude that IPC should be considered in the evaluation and differential diagnosis of cystic lesions observed in postmenopausal women. Today, the removal of the mass with a negative surgical margin is deemed sufficient as its treatment. However, the decision to pursue adjuvant therapy should be determined on a case-by-case basis, taking into consideration the characteristics of the tumour itself, and additional prospective multicentre studies should be conducted.

Authors declare no conflict of interest.

References

- Solorzano CC, Middleton LP, Hunt KK, et al. Treatment and outcome of patients with intracystic papillary carcinoma of the breast. *Am J Surg* 2002; 184: 364-8.
- Hariprasad S, Hariprasad P, Srinivas T. Intracystic papillary carcinoma of the breast in males: a case report and review of the literature. *J Clin Diagn Res* 2013; 7: 568-70.
- Ait Benkaddour Y, El Hasnaoui S, Fichtali K, Fakhir B, Jalal H, Kouchani M, Aboufalah A, Abbassi H. Intracystic papillary carcinoma of the breast: report of three cases and literature review. *Case Rep Obstet Gynecol* 2012; 2012: 979563.
- Dogan BE, Whitman GJ, Middleton LP, Phelps M. Intracystic papillary carcinoma of the breast. *AJR Am J Roentgenol* 2003; 181 (1): 186.
- Yamamoto H, Okada Y, Taniguchi H, et al. Intracystic papilloma in the breast of a male given long term phenothiazine therapy: a case report. *Breast Cancer* 2006; 13: 84-8.
- Muallaoglu S, Ozdemir E, Kutluay L. Intracystic papillary carcinoma of the breast in a male patient: a case report. *Case Rep Med* 2012; 2012: 378157.
- Wagner AE, Middleton LP, Whitman GJ. Intracystic papillary carcinoma of the breast with invasion. *AJR Am J Roentgenol.* 2004; 183 (5): 1516.
- Akagi T, Kinoshita T, Shien T, Hojo T, Akashi-Tanaka S, Murata Y. Clinical and pathological features of intracystic papillary carcinoma of the breast. *Surg Today* 2009; 39: 5-8.
- Lefkowitz M, Lefkowitz W, Wargotz ES. Intraductal (intracystic) papillary carcinoma of the breast and its variants: a clinicopathological study of 77 cases. *Hum Pathol* 1994; 25: 802-9.
- Grabowski J, Salzstein SL, Sadler GR, Blair S. Intracystic papillary carcinoma: a review of 917 cases. *Cancer* 2008; 113: 916-20.
- Levine PH, Waisman J, Yang GC. Aspiration cytology of cystic carcinoma of the breast. *Diagn Cytopathol* 2003; 28: 39-44.
- Brookes MJ, Bourke AG. Radiological appearances of papillary breast lesions. *Clin Radiol* 2008; 63: 1265-73.
- Reefy SA, Kameshki R, Sada DA, Elewah AA, Awadhi AA, Awadhi KA. Intracystic papillary breast cancer: a clinical update. *Ecancermedicalscience* 2013; 7: 286.
- Carter D, Orr SL, Merino MJ. Intracystic papillary carcinoma of the breast. After mastectomy, radiotherapy or excisional biopsy alone. *Cancer.* 1983; 1: 14-9.
- Leal C, Costa I, Fonseca D, Lopes P, Bento MJ, Lopes C. Intracystic (encysted) papillary carcinoma of the breast: a clinical, pathological, and immunohistochemical study. *Hum Pathol* 1998; 29: 1097-104.
- Fayanju OM, Ritter J, Gillanders WE, Eberlein TJ, Dietz JR, Aft R, Margenthaler JA. Therapeutic management of intracystic papillary carcinoma of the breast: the roles of radiation and endocrine therapy. *Am J Surg* 2007; 194: 497-500.
- Grabowski J, Salzstein SL, Sadler GR, Blair S. Intracystic papillary carcinoma: a review of 917 cases. *Cancer* 2008; 113: 916-20.

18. Mugler KC, Marshall C, Hardesty L, Finlayson C, Singh M. Intracystic papillary carcinoma of the breast: differential diagnosis and management. *Oncology (Williston Park)* 2007; 21: 871-6.
19. Dragoumis DM, Tsiftoglou AP. Intracystic papillary carcinoma associated with ductal carcinoma in situ in a male breast. *J Postgrad Med* 2008; 54: 39-40.
20. Mulligan AM, O'Malley FP. Metastatic potential of encapsulated (intracystic) papillary carcinoma of the breast: a report of 2 cases with axillary lymph node micrometastases. *Int J Surg Pathol* 2007; 15: 143-7.

Address for correspondence

Assist. Prof. Dr. **Emine Canyilmaz**, MD
Department of Radiation Oncology, School of Medicine
Karadeniz Technical University
Trabzon, Turkey
tel. +90 462 377 56 01
fax +90 462 325 22 70
e-mail: dremocan@yahoo.com

Submitted: 9.02.2013

Accepted: 7.08.2013